

Syndromic Deafness – Variant of Waardenburg syndrome

¹, Dr. Basavaraj Belaldavar (MS. ENT), ², Dr. Vini Balakrishnan (PG in ENT)
^{1,2}, J. N Medical College KLE University Belgaum

ABSTRACT: Childhood deafness is quite bothersome and a common problem. EBM documents that serious hearing impairment is found in one in 800 newborns. Amongst the 50 percent of permanent childhood deafness, 30 percent is syndromic and is thought to be because of abnormal genetic makeup. Syndromic cases of deafness are more accurately diagnosed by the associated additional features of the syndrome. Waardenburg syndrome is a rare, autosomally inherited disorder with distinct clinical manifestations of dystopia canthorum, white forelock, congenital hearing loss and heterochromia iridis. Herewith, we are reporting 2 siblings who presented with deaf mutism and with clinically significant notable variations suggestive of a rare presentation of type 1 and type 2 Waardenburg syndrome in the same family.

KEY WORDS: Waardenburg syndrome, deaf mutism, syndromic deafness

I. INTRODUCTION:

Hearing loss is the most common sensory deficit in humans. Hereditary deafness is genetically a highly heterogeneous disease with many different genes responsible for auditory dysfunction. To complicate things further, different mutation in one gene can cause variable phenotype. Congenital hearing loss occurs with a prevalence of about 1-3/1000. About 60% of prelingual deafness is attributed to genetic defects. Among hereditary hearing impairment, 15-30% are syndromic, whereas the vast majority are non-syndromic (70%).¹ Waardenburg syndrome (WS) is a rare, autosomally inherited and genetically heterogeneous disorder of neural crest cell derived tissues. The prevalence figures vary from 1:20,000 to 1:40,000.² The syndrome is named after a Dutch ophthalmologist and geneticist, Petrus Johannes Waardenburg, who in 1951, described a syndrome comprising of six characteristic features - lateral displacement of the medial canthi and lacrimal punctae, broad and high nasal root, hypertrichosis of medial part of eyebrows, partial or total heterochromia iridis, white forelock and congenital deaf-mutism. Since then, four subtypes (I to IV) with variable penetrance and gene expression of different clinical features have been described: Type 1 with dystopia canthorum; Type 2 without; Type 3 (Klein-Waardenburg syndrome), which is similar to type 1 and includes upper limb abnormalities; and type 4 (Waardenburg-Shah syndrome) which is type 2 with Hirschsprung disease.¹ WS accounts for about 2 to 5% cases of congenital deafness.³ WS 1 and 2 are autosomal dominant inherited in most cases, WS 3 is usually sporadic, but when it occurs in families, inheritance is autosomal dominant and WS 4 is autosomal recessive in inheritance. Waardenburg syndrome can be diagnosed easily in the first few months of life because of prominent phenotypic features. Earlier diagnosis means a more successful rehabilitation of hearing.

We report 2 siblings who presented to us with deaf mutism and typical clinical features suggesting a rare presentation of Type 1 and Type 2 Waardenburg syndrome in the same family.

II. CASE REPORT:

Case 1:

A 4 year old boy (proband) presented to us with complaints of inability to respond to sounds and inability to speak since birth. He was born out of a second degree consanguineous marriage at full term after an uneventful pregnancy. Neither of the parents were affected. Examination of child revealed deaf mutism with no response to clap test. Physical examination revealed a white forelock. There was an area of hypopigmentation of skin (congenital leukoderma) over the midline of forehead, extending to root, bridge and dorsum of nose. Hypopigmentation and flaring of medial eyebrows and hypopigmentation of bilateral upper eyelashes was also noted. Both his eyes showed complete iris hypopigmentation (sapphire blue eyes)(Fig 1). In addition, he had dystopia canthorum and broad nasal root(Fig 2). Fundus examination revealed generalised hypopigmentation in both eyes. Interestingly, the point to be noted in this case is the obvious presence of frontal bossing (Fig 3). Association of frontal bossing has been reported only once in literature.⁴ Routine laboratory investigations and clinical systemic examination were within normal limits. The child's hearing was unresponsive to pure tone audiometry investigation. Auditory brainstem response demonstrated sensorineural hearing loss.

Case 2:

A 6 year old brother of the proband was also found to have congenital deaf mutism. Examination revealed broad nasal root with wide intercanthal distance. His right eye showed complete iris hypopigmentation and left eye showed normal colored iris with segmental iris hypopigmentation (Fig. 4). There was no dystopia canthorum or medial eyebrow flare. Fundus examination showed decrease in retinal pigmentation with focal hypopigmentation lesion in both eyes. No other abnormalities such as, hair or skin pigmentation was found. Auditory brainstem response revealed severe degree sensorineural deafness with hearing threshold of 110 dB in Right ear and profound degree hearing loss in Left ear (Fig. 5). Due to the absence of dystopia canthorum, this child was diagnosed as Waardenburg Type 2, whereas case 1, with dystopia canthorum was diagnosed as Waardenburg Type 1.

III. DISCUSSION:

WS is a dominantly inherited example of auditory pigmentary syndrome with patchy depigmentation of skin, hair, eyes or stria vascularis of cochlea. Both, the auditory and pigmentary could be explained by a failure of proper melanocyte differentiation. There is no requirement for melanin in the cochlea but in the absence of melanocytes, the stria is abnormally thin, no endocochlear potential is generated and Reissner's membrane collapses leading to destruction of Organ of Corti leading to sensorineural hearing loss. With the exception of those in the retina, melanocytes are derived from the embryonic neural crest. Other tissues derived from the neural crest that are involved in WS1 and the rarer WS3 and WS4 variants include the frontal bone, limb muscles, and enteric ganglia respectively.⁵

Five different genes on 5 different chromosomes have been identified. The genetics of WS highlight the fact that one phenotypic syndrome can be caused by mutations in more than one gene. WS1 and WS3 are associated with PAX-3 gene mutation on chromosome 2q37. PAX-3 is a DNA binding protein that is important in determining the fate of neural crest cells in the developing nervous system. WS2 is associated with mutation of MITF gene (Microphthalmia Transcription Factor Gene on chromosome 3p). In type 4, 3 different genes are implicated: EDN3, EDNRB and SOX10. EDN3 stimulates the proliferation and melanogenesis of neural crest cells. An essential role for EDNRB is postulated in the normal development of two crest neural crest cell derived cell lineages, epidermal melanocytes and enteric neurons. SOX10 belongs to the family of transcription factors that bind DNA and regulate its transcription.¹

Diagnostic criteria for Waardenburg syndrome types 1 and 2: Table 1

Diagnosis in our cases:

In our report, case1 satisfies all the variables in the criteria for Waardenburg type1 which occurs very rarely.⁶ In the first report by Waardenburg, only 6 out of 178 of his cases had all the abnormalities of the syndrome.⁴

Case 2 satisfies 3 major criteria and 1 minor criteria with absence of dystopia canthorum and fits into the diagnosis for Waardenburg type2.

Sensorineural hearing loss and heterochromia iridum are the two most characteristic features of WS2. Both are more common in WS2 than WS1. White forelock and leukoderma are both more common in WS1 than in WS.²

Dystopia canthorum: (Fig 5)

Dystopia canthorum is the most penetrant feature of WS1, being present in 90% of those affected.⁵ It is diagnosed clinically by a variety of indices of which the best is the W index, developed by Arias and Mota.⁷

The W index for our cases were 2.11 for case 1(a=37, b=60, c=92) and 1.88 for case 2(a=30, b=53, c=80), thus excluding dystopia canthorum in case 2.

Eye colour:

Iris heterochromia maybe complete or partial. In complete heterochromia, each iris is a different colour, while in partial heterochromia, sharply demarcated areas of normal and abnormal iris colours exist. Hypoplastic blue irises are associated with severe to profound hearing loss and more common in WS1 than in WS2 as is seen in our first case.⁵ Hypoplastic blue eyes is more closely associated with WS1 (15-18%) than WS2 (3-23%) and Heterochromia iridis is more closely associated with WS2 (42-54%) than WS1 (15-31%).²

White forelock:

A distinctive white forelock is usually seen in the midline, but maybe elsewhere in the head. It may be present from birth or appear later, usually in the teens, when it is considered to represent premature greying (defined by the Waardenburg Consortium as predominance of white hair appearing before the age of 30 years). Pigmentation defects can affect the eyebrows and eyelashes as is demonstrated in our first case. White forelock is more strongly seen in type 1 (43-48%) than type 2 (16-23%).²

Skin signs:

Hypopigmentation of the skin is congenital and maybe found on the face, trunk or limbs.⁵ It may be associated with an adjacent white forelock as seen in case 1.

Hearing:

The hearing loss in WS is sensorineural, congenital and usually non-progressive. It varies in severity from slight to profound. In our study, case 1 demonstrated profound hearing loss, while case 2 showed severe degree hearing loss. Case 2 had a hearing threshold of 110db in right ear and thus the child was rehabilitated with hearing aid.

CONCLUSION:

The presentation of this article is undertaken to enlighten a rare presentation of a rare disease. This study brings light to the possibility of 2 types of Waardenburg syndrome (WS1 and WS2) in the same family with no family history of the disease. The association of frontal bossing with WS maybe explained by development of some of the craniofacial skeletal tissue by neural crest cells, but the reason for the rarity of this feature in Waardenburg syndrome is yet to be explained.⁸ The peculiar features of the syndrome helps in early diagnosis and therefore, early hearing rehabilitation may lighten the stress and helps in rehabilitation of these patients in society for equalization of opportunities and social integration.

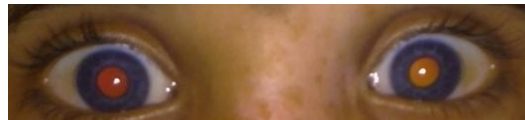

Figure 1: Bilateral hypoplastic blue iridis

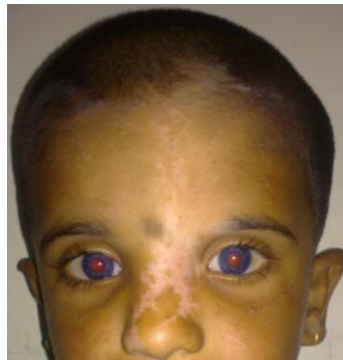

Figure 2: White forelock , dystopia canthorum, broad nasal root, hypoplastic nasal alae, medial eyebrow flare, hypopigmentation over forehead and dorsum of nose and hypopigmentation of medial eyebrows

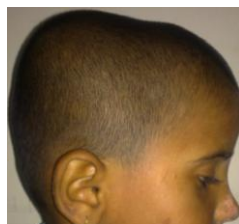

Figure 3: Frontal bossing

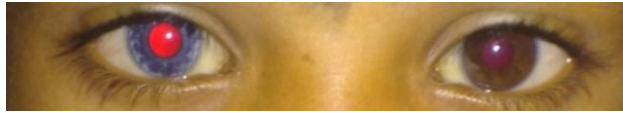

Figure 4: Heterochromia iridis

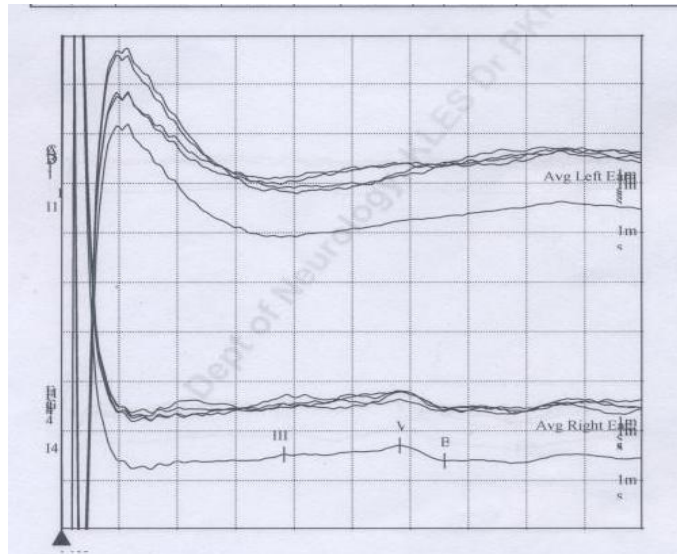


Figure 5: Auditory brainstem response for Case 2 revealed severe degree sensorineural deafness with hearing threshold of 110 dB in Right ear and profound degree hearing loss in Left ear.

Table 1: Diagnostic Criteria for WS proposed by Waardenburg Consortium^[4]

Major Criteria

- Congenital sensorineural hearing loss.
- Pigmentary disturbances of iris; complete heterochromia iridis, partial or segmental heterochromia iridis, hypoplastic blue iridis.
- White forelock.
- Dystopia canthorum.
- Affected first degree relative

Minor Criteria

- Congenital leucoderma: several areas of hypopigmented skin
- Medial eyebrow flare (Synophrys)
- Broad and high nasal root
- Hypoplasia of alae nasi
- Premature graying of hair

Diagnostic criteria for WS 1 : 2 major or 1 major + 2 minor criteria

Diagnostic criteria for WS 2 : 2 major features. The major features are as in the list below except for exclusion of dystopia canthorum and inclusion of premature greying

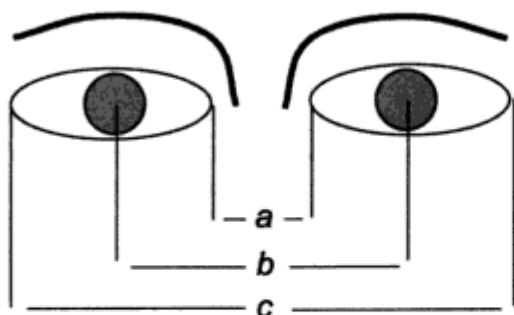


Figure 1 Method of calculating the W index for dystopia canthorum. (1) Measure a (inner canthal distance), b (interpupillary distance), and c (outer canthal distance) in millimeters using a rigid ruler held against the forehead. (2) Calculate $X = (2a - 0.2119c - 3.909)/c$. (3) Calculate $Y = (2a - 0.2479b - 3.909)/b$. (4) Calculate $W = X + Y + a/b$. Dystopia is present when $W > 1.95$.

REFERENCES:

- [1]. Gurtler N, Lalwani A. K. Etiology of syndromic and nonsyndromic sensorineural hearing loss. *Otolaryngol Clin N Am.* 35 (2002) 891-908.
- [2]. Milunsky J. Waardenburg Syndrome Type I. *Gene Reviews* 1993-2001 Jul 30.
- [3]. Nayak CS, Isaacson G. Worldwide distribution of Waardenburg syndrome. *Ann Otol Rhinol Laryngol.* 2003 Sep; 112 :817-20.
- [4]. C. H. Tay. Waardenburg's syndrome and familial periodic paralysis. *Postgrad Med J.* 1971 June; 47(548): 354–360.
- [5]. Read AP, Newton VE (1997) Waardenburg syndrome. *J Med Genet* 34:656-65.
- [6]. Ghosh SK, Bandyopadhyay D, Ghosh A, Biswas SK, Mandal RK. Waardenburg syndrome: A report of three cases. *Indian J Dermatol Venereol Leprol* 2010;76:550.
- [7]. Arias S, Mota M. Apparent non-penetrance for dystopia in Waardenburg syndrome type I, with some hints in the diagnosis of dystopia canthorum. *J Genet Hum* 1978;26:103-31.
- [8]. Bondurand N et al. Deletions at the *SOX10* Gene Locus Cause Waardenburg Syndrome Types 2 and 4. *Am. J. Hum. Genet.* 2007;81:1169–1185.